



## Vanishing Bile Duct Syndrome due to Valproic Acid: A Rare Case

Jean Rodrigo Tafarel<sup>1</sup>, Isabela Busto Silva<sup>2</sup>, Isadora Busto Silva<sup>3\*</sup>,  
Luiz Augusto Fanhani Cracco<sup>2</sup>, Vanessa Martins Torres<sup>2</sup> and Larissa  
Uhlmann Wendling<sup>4</sup>

<sup>1</sup>Gastroenterologist and Hepatologist, Internal Medicine Department, Hospital  
Universitário Cajuru, Curitiba, Parana, Brazil

<sup>2</sup>Medical Resident Internal Medicine Department, Hospital Universitário Cajuru,  
Curitiba, Parana, Brazil

<sup>3</sup>Medical Student, Federal University of Paraná, Curitiba, Parana, Brazil

<sup>4</sup>Pathologist, Curitiba, Parana, Brazil

**\*Corresponding Author:** Isadora Busto Silva, Medical Student, Federal University  
of Paraná, Martin Afonso, Curitiba, Parana, Brazil.

**Received:** August 03, 2021

**Published:** September 08, 2021

© All rights are reserved by **Isadora Busto  
Silva., et al.**

### Abstract

Vanishing bile duct syndrome (VBDS) is a rare acquired condition, described by the progressive loss of intrahepatic bile ducts, leading to ductopenia and cholestasis. It can be associated with adverse drug reactions, cancer, and autoimmune liver diseases. The diagnosis is confirmed when there are less than 50% of the bile ducts on histopathological analysis. The prognosis is variable and it depends on the etiology of the bile duct injury. We report a case of a 47-year-old man with chronic cholestatic condition associated with the use of valproic acid, in which the investigation confirmed VBDS in the histopathological analysis.

**Keywords:** Adverse Drug Reaction; Bile Duct Disease; Cholestasis; Case Report; Vanishing Bile Duct Syndrome

### Abbreviations

VBDS: Vanishing Bile Duct Syndrome; MRCP: Magnetic Resonance Cholangiopancreatography; AMA: Anti-Mitochondria Antibody; PBC: Primary Biliary Cholangitis; CMV: Cytomegalovirus; DILI: Drug-Induced Liver Injury

### Introduction

Vanishing bile duct syndrome (VBDS) refers to a group of acquired disorders that result in the destruction and progressive disappearance of intrahepatic bile ducts associated with cholestasis [1]. The diagnosis can be suggested by imaging, such as magnetic resonance cholangiopancreatography (MRCP) and confirmed by histopathological analysis [2]. There are multiple etiologies involved, including autoimmune and neoplastic disorders, medications, genetic abnormalities, and infectious diseases [1,2]. Several

drugs have been associated with the VBDS, antibiotics being the most related group [3].

Prognosis and treatment depends on the etiology and degree of liver involvement. In cases related to drug cause, its suspension tends to produce regression of the lesion and laboratory improvement within weeks [1,2]. However, some patients may experience progressive loss of the bile ducts, resulting in secondary cirrhosis, liver failure, need for liver transplantation and death [1-3]. The purpose of this report is to describe a case of VBDS, as well as to comment on the main clinical aspects of the entity.

### Case Report

A 47-year-old white male, with a history of cluster headache for the last 2 years, presented intense itching, jaundice and choloria in a progressive worsening. There was no fever, weight loss or family

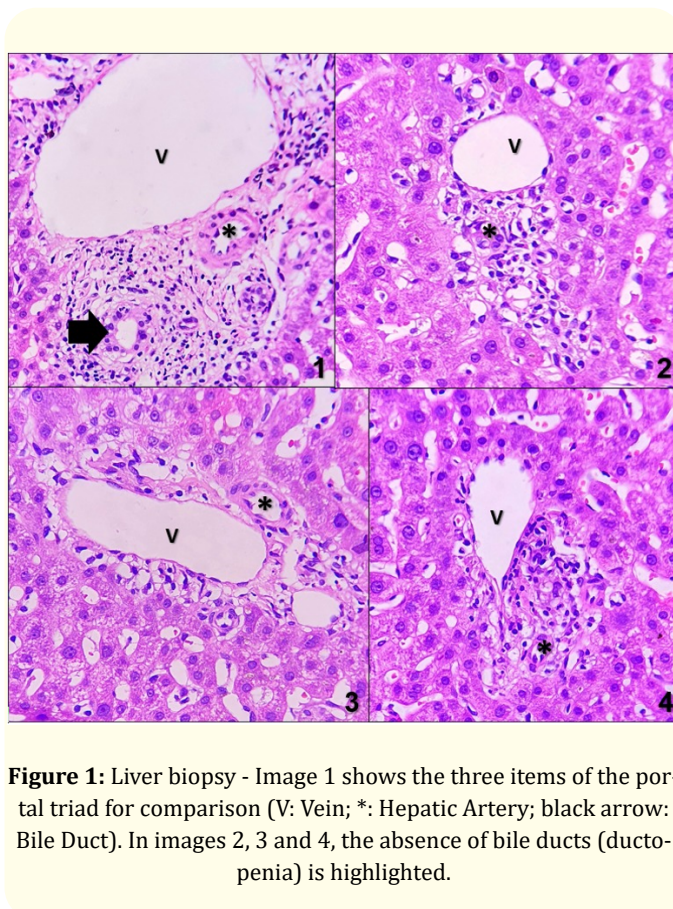
history of liver diseases. He reported headache control with daily use of valproic acid, amitriptyline and verapamil. There was no report of illicit drug usage and alcohol, a recent trip or any epidemiological data on leptospirosis. On physical examination, he had severe cutaneous-mucosal jaundice and no signs of chronic liver disease.

The patient laboratory tests confirmed cholestatic jaundice (Table 1). Serological markers of hepatitis B and C and anti-mitochondria antibody (AMA) were negative, excluding viral cholestatic hepatitis and primary biliary cholangitis (PBC).

Laboratory tests	Reference value	Investigation	After treatment
Total bilirubin	0,30 - 1,20 mg/dL	9,22 mg/dL	0,77 mg/dL
Direct bilirubin	< 0,20 mg/dL	8,92 mg/dL	0,21 mg/dL
Indirect bilirubin	< 1,10 mg/dL	0,30 mg/dL	0,56 mg/dL
Gamma glutamyl transferase	8 - 61 U/L	2510 U/L	1286 U/L
C-reactive protein	< 5,0 mg/L	25,0 mg/L	-
Alkaline phosphatase	40 - 120 U/L	287 U/L	208 U/L
Alanine aminotransferase	10 - 50 U/L	267 U/L	45 U/L
Aspartate aminotransferase	10 - 50 U/L	109 U/L	33 U/L
Prothrombin activity time	9,9 - 13,9 seconds	12 seconds	12 seconds
AgHBs	Non-reactive	Non-reactive	-
Anti-HCV	Non-reactive	Non-reactive	-
Anti-mitochondria antibody	Non-reactive	Non-reactive	-

**Table 1:** Laboratory tests over the time with a 3-month-interval between results.

The patient underwent to an abdomen ultrasound examination, which did not detect biliary tract dilatation or cholelithiasis or choledocholithiasis. Even so, the MRCP was performed, which suggested presence of intrahepatic ductopenia and hypodistended gallbladder. There were no signs of primary sclerosing cholangitis, lithiasis or neoplasm in MRCP. As the main causes of cholestatic injury were ruled out, an ultrasound guided liver biopsy was performed (Figure 1) to evaluate drug-induced liver injury and AMA-negative PBC.



**Figure 1:** Liver biopsy - Image 1 shows the three items of the portal triad for comparison (V: Vein; \*: Hepatic Artery; black arrow: Bile Duct). In images 2, 3 and 4, the absence of bile ducts (ductopenia) is highlighted.

Histopathological analysis revealed signs of ductopenia in 6 out of 10 portal triads (60%). A second analysis of the same liver specimen was performed, and the findings confirm VBDS. There were no histological signs of PBC, fibrosis, steatosis, neoplasm, viral disease or siderosis.

The etiological role of valproic acid was inferred and it was discontinued. To control cholestasis, empiric use of Ursodeoxycholic Acid (13 mg/Kg/day) for a 30-day-period was proposed. After 3 months, the patient presented clinical (resolution of jaundice, pruritus and choluria) and laboratory improvement (Table 1).

**Discussion and Conclusion**

Vanishing bile duct syndrome is an acquired disorder, in which etiopathogenesis involves the destruction and progressive disappearance of the intrahepatic bile ducts [1-5]. This condition represents only 0.5% of the diseases of the small bile duct [3]. It is marked by ductopenia, evidenced in liver biopsy, which consists of a 50% reduction in the number of intrahepatic bile ducts [6].

Autoimmune disorders, medication, genetic abnormalities, infectious diseases and neoplastic disorders such as Hodgkin's lymphoma have been described as responsible for the description of the syndrome [1,2]. However, Primary Biliary Cholangitis (PBC) is the most widely recognized cause of ductopenia in adults [7]. Diagnosis should be considered in patients with elevated alkaline phosphatase without extrahepatic biliary obstruction, and in patients with unexplained pruritus, fatigue, jaundice, or unintentional weight loss [7]. In our case, there were no histological signs of PBC and AMA was negative.

Infectious agents are also associated with ductopenia. Neonatal exposure to cytomegalovirus (CMV), syphilis and rubella has been implicated in biliary shortage [8]. In addition, neoplastic disorders are included in the etiopathogenesis of the syndrome. Secondary cholestasis due to bile duct loss is a rare presentation of Hodgkin's lymphoma [1,2]. Histological analysis of our case did not show signs of neoplasia or any infectious agents.

Drug-induced liver injury (DILI) is one of the leading causes of liver injury and it can be a reason of acute liver failure [2]. VBDS can be a type of DILI presented with progressive cholestasis [9]. The disorder has been associated with more than forty drugs, including chlorpromazine, amoxicillin, valproic acid and carbamazepine [1,3,10,11]. The majority of liver reactions are idiosyncratic, starting from 5 to 90 days after the causative drug was taken. The main DILI histological findings are hepatitis, nodular hyperplasia, steatosis, cholestasis, fibrosis, sinusoidal damage, granuloma formation and VBDS [12].

In our case, valproic acid was suspected as the cause of VBDS. Despite older age is a risk factor for DILI, valproic acid tends to induce liver damage in younger people [12].

VBDS clinical course and manifestations are variable, with canalicular enzymes rising, pruritus, and when the disease is severe and prolonged, there may be formation of gallstones, hyperlipidemia, xanthelasma and fat-soluble vitamin deficiencies [6].

Complementary laboratory investigation should include tests for viral and autoimmune liver disease (such as PBC), as well imaging exams to exclude extrahepatic biliary obstruction and neoplasms [6]. In the presented case, all tests excluded the presence of these etiologies.

When considering VBDS, imaging tests (such as MRCP) have less sensitivity to detect ductopenia than liver biopsy. Liver biopsy assesses the severity of liver disease too.

Ductopenia is present when there is loss of interlobular bile ducts above 50% of the portal tracts, in a pathological sample with at least 10 portal tracts [1,2,4,13]. The patient in this report presented signs of ductopenia in 6 out of 10 observed portal tracts. Correlating the clinical, laboratory and radiological exams, and excluding other possibilities, the observed histological features were consistent with the hypothesis of VBDS.

VBDS is followed by uncomfortable symptoms such as pruritus. Therefore, treatment may include antihistamines, such as diphenhydramine and hydroxyzine [13]. There is no benefit of using corticosteroids in the treatment of severe cholestasis due to VBDS. Despite Ursodeoxycholic Acid is widely applied in the cholestasis liver diseases, there are no randomized clinical trials demonstrating in DILI [13]. Experimental approaches include immunosuppression with calcineurin inhibitors or monoclonal antibodies [13]. In the case reported, after establishing the diagnosis, valproic acid was suspended and empirical treatment with Ursodeoxycholic Acid was done, with progressive clinical and laboratory improvement after a 3-month-period.

The clinical progression is unknown, because the disease can progress to a worse scenario with biliary cirrhosis or to a better one, characterized by biliary epithelial regeneration with clinical recovery over months for years [6,13]. The result is usually unpredictable, and it depends on the underlying etiology of the bile duct loss and available treatments.

### Conflict of Interest

The authors declare no conflict of interest.

### Bibliography

1. Greca Raquel D., *et al.* "Vanishing bile duct syndrome related to DILI and Hodgkin lymphoma overlap: A rare and severe case". *Annals of Hepatology* 19.1 (2020): 107-112.
2. Bakhit Mena., *et al.* "Vanishing bile duct syndrome in Hodgkin's lymphoma: A case report and literature review". *World Journal of Gastroenterology* 23.2 (2017): 366.
3. Sundaram Vinay and Björnsson Einar S. "Drug-induced cholestasis". *Hepatology Communications* 1.8 (2017): 726-735.

4. Bak Haein., *et al.* "A Case of Vanishing Bile Duct Syndrome after Drug-Induced Liver Injury Caused by Pelubiprofen". *Yonsei Medical Journal* 61.12 (2020): 1060.
5. Bryant Alton E and Dreifuss Fritz E. "Valproic acid hepatic fatalities. III. US experience since 1986". *Neurology* 46.2 (1996): 465-469.
6. Ludwig J., *et al.* "Idiopathic adulthood ductopenia. A cause of chronic cholestatic liver disease and biliary cirrhosis". *Journal of Hepatology* 7.2 (1988): 193-199.
7. Miyakawa H., *et al.* "Detecção de autoanticorpos antimitocondriais em pacientes imunofluorescentes AMA-negativos com cirrose biliar primária usando auto-antígenos recombinants". *Hepatology* 34 (2001): 243.
8. Sherlock Sheila. "The syndrome of disappearing intrahepatic bile ducts". *The Lancet* 330.8557 (1987): 493-496.
9. Zoubek ME., *et al.* "Systematic review: ibuprofen-induced liver injury". *Alimentary Pharmacology and Therapeutics* 51 (2020): 603-611.
10. Hussaini S Hyder and Farrington Elizabeth A. "Idiosyncratic drug-induced liver injury: an overview". *Expert Opinion on Drug Safety* 6.6 (2007): 673-684.
11. Levine Calley., *et al.* "Severe ductopenia and cholestasis from levofloxacin drug-induced liver injury: a case report and review. In: Seminars in liver disease". *Thieme Medical Publishers* (2014): 246-251.
12. Leise Michael D., *et al.* "Drug-induced liver injury". In: Mayo clinic proceedings. Elsevier (2014): 95-106.
13. Síndrome do desaparecimento do ducto biliar". *LiverTox: Informações clínicas e de pesquisa sobre lesão hepática induzida por drogas*. Bethesda (MD): Instituto Nacional de Diabetes e Doenças Digestivas e Renais (2012).

**Volume 4 Issue 10 October 2021**

**© All rights are reserved by Isadora Busto Silva., *et al.***